



Aplastic anemia

Authors: Peter Maslak

Category: Bone marrow failure > Acquired Bone marrow failure > Acquired Aplastic Anemia

Number of Units: 3

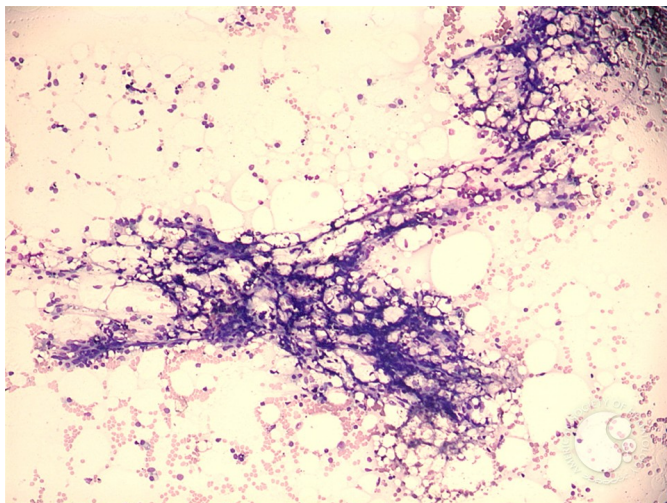
Aplastic anemia - 1.

Image ID: 3909

Authors: Peter Maslak

Category: Bone marrow failure > Acquired Bone marrow failure > Acquired Aplastic Anemia

Description: Spicules are empty and generally devoid of hematopoietic elements.



Copyright © 2026 American Society of Hematology. Copyright restrictions may apply.



ASH Image Bank™

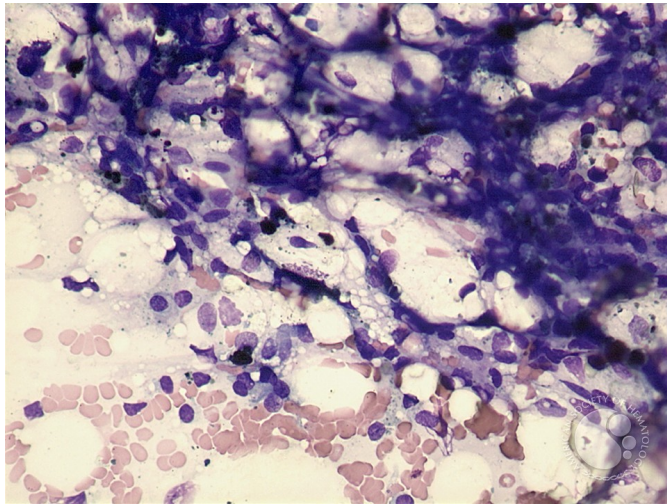
Aplastic anemia - 2.

Image ID: 3910

Authors: Peter Maslak

Category: Bone marrow failure > Acquired Bone marrow failure > Acquired Aplastic Anemia

Description: Spicules are composed almost entirely of stromal elements.



Copyright © 2026 American Society of Hematology. Copyright restrictions may apply.

Aplastic anemia - 3.

Image ID: 3911

Authors: Peter Maslak

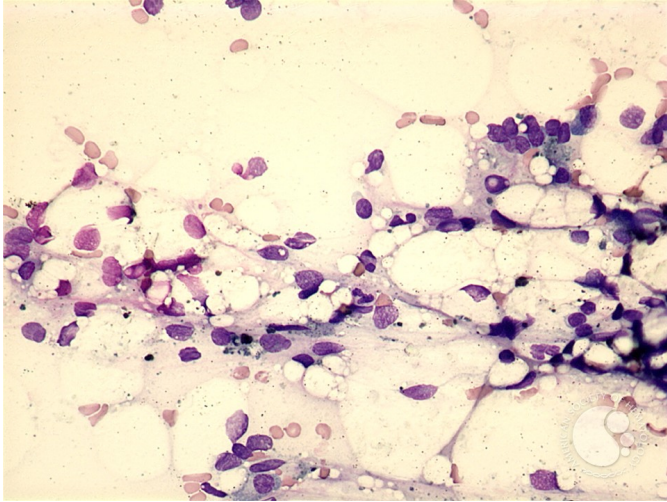
Category: Bone marrow failure > Acquired Bone marrow failure > Acquired Aplastic Anemia

Description: A high-power view shows naked nuclei and debris laden histiocytes.





ASH Image Bank™



Copyright © 2026 American Society of Hematology. Copyright restrictions may apply.

