



ASH Image Bank™

Schistocytes

Authors: Peter Maslak

Category: Red Cell: Hemolytic Anemia (HA)

Number of Units: 1

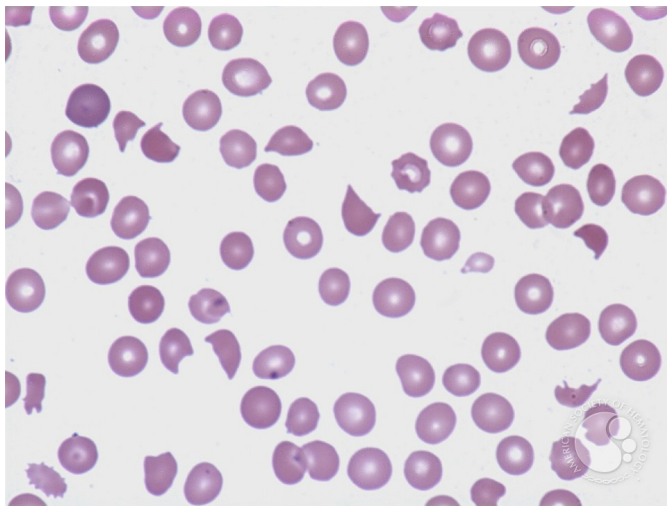
Schistocytes - 1.

Image ID: 3718

Authors: Peter Maslak

Category: Red Cell: Hemolytic Anemia (HA)

Description: Peripheral smear from a patient with DIC shows characteristic "helmet" cells.



Copyright © 2026 American Society of Hematology. Copyright restrictions may apply.

