



Megakaryocyte Fragment

Authors: Jon Fukumoto

Category: Myeloid Neoplasms and acute leukemia (WHO 2016) > Myeloproliferative Neoplasms (MPN) > Primary Myelofibrosis (PMF)

Number of Units: 1

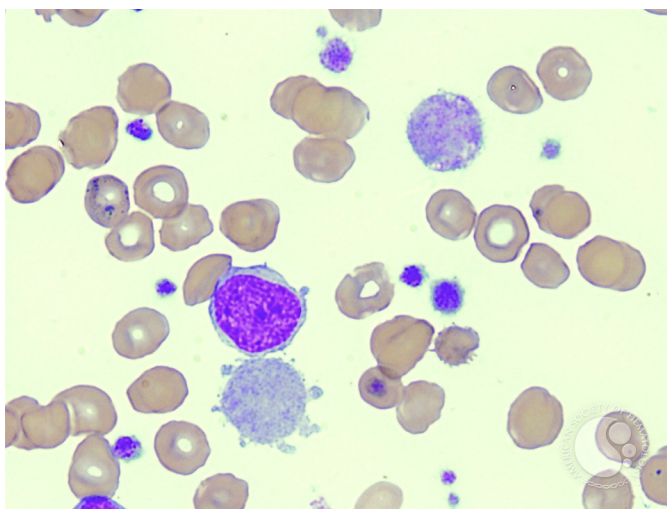
Megakaryocyte Fragment - 1.

Image ID: 3202

Authors: Jon Fukumoto

Category: Myeloid Neoplasms and acute leukemia (WHO 2016) > Myeloproliferative Neoplasms (MPN) > Primary Myelofibrosis (PMF)

Description: Megakaryocyte fragment (bottom), adjacent to a megakaryoblast, in a patient with idiopathic myelofibrosis (MF) transforming to acute myelogenous leukemia (AML). Normal and giant platelets are also present.



Copyright © 2026 American Society of Hematology. Copyright restrictions may apply.