



Ehrlichiosis

Authors: Peter Maslak; Lisa Southern;

Category: Bin > Miscellaneous

Number of Units: 2

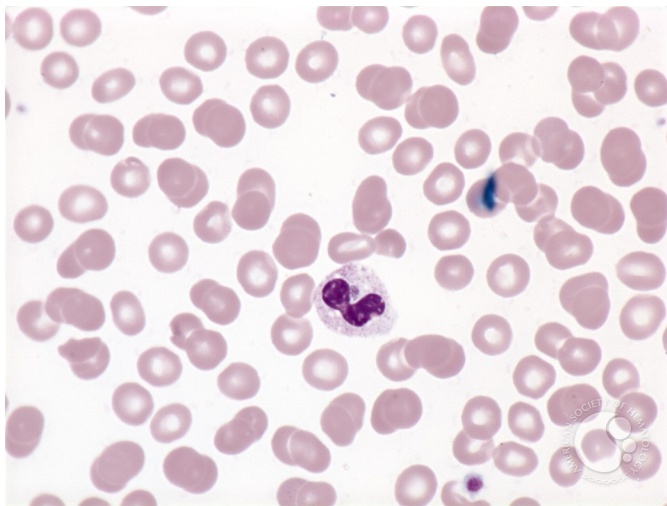
Ehrlichiosis - 1.

Image ID: 1816

Authors: Peter Maslak; Lisa Southern;

Category: Infectious Disease > Bacteria > Ehrlichia

Description: Characteristic intracytoplasmic inclusions (arrow) seen in a granulocyte of a patient infected with ehrlichia.



Copyright © 2026 American Society of Hematology. Copyright restrictions may apply.



ASH Image Bank™

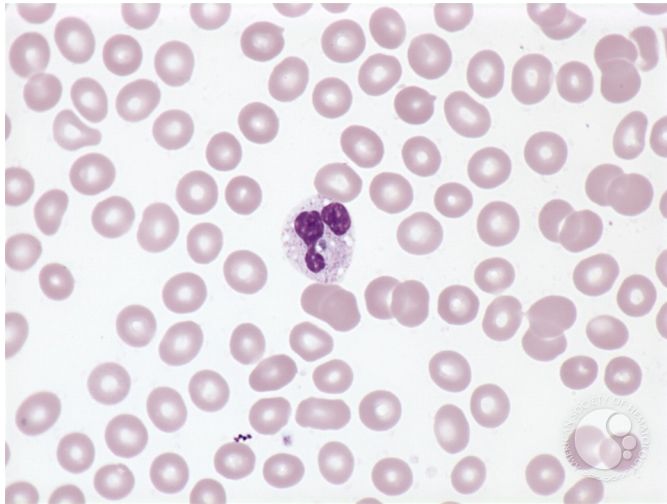Ehrlichiosis - 2.

Image ID: 1817

Authors: Peter Maslak; Lisa Southern;

Category: Infectious Disease > Bacteria > Ehrlichia

Description: Morula (arrow) in a granulocyte of a patient with ehrlichiosis. Vacuoles are also noted in the cytoplasm.



Copyright © 2026 American Society of Hematology. Copyright restrictions may apply.

