



ASH Image Bank™

Refractory anemia with ringed sideroblast associated with thrombocytosis

Authors: John Lazarchick

Category: Myeloid Neoplasms and acute leukemia (WHO 2016) > Myeloproliferative Neoplasms (MPN) > MPN, unclassifiable

Number of Units: 4

Refractory anemia with ringed sideroblast associated with thrombocytosis - 1.

Image ID: 4028

Authors: John Lazarchick

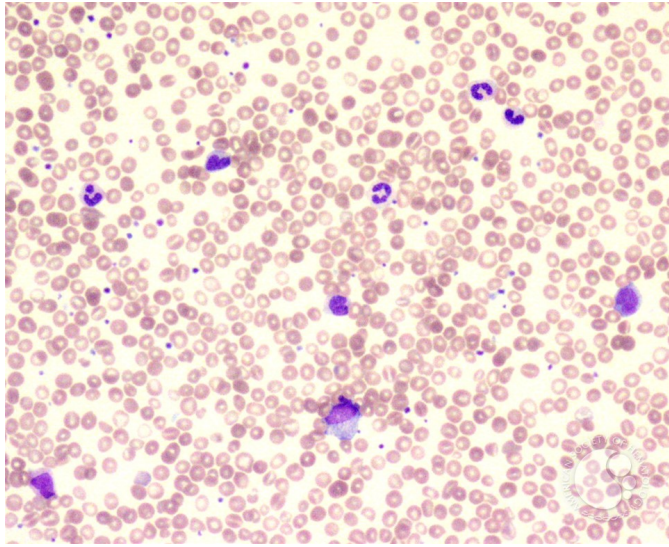
Category: Myeloid Neoplasms and acute leukemia (WHO 2016) > Myeloproliferative Neoplasms (MPN) > MPN, unclassifiable

Description: Peripheral smear from a patient with a diagnosis of refractory anemia with ringed sideroblasts and thrombocytosis. CBC showed a hemoglobin of 9g/dl, WBC 15,000/ul and platelet count of 460,000/ul. Note presence of few immature myeloid precursors and increased platelet with large forms present.





ASH Image Bank™



Copyright © 2026 American Society of Hematology. Copyright restrictions may apply.

Refractory anemia with ringed sideroblast associated with thrombocytosis - 4.

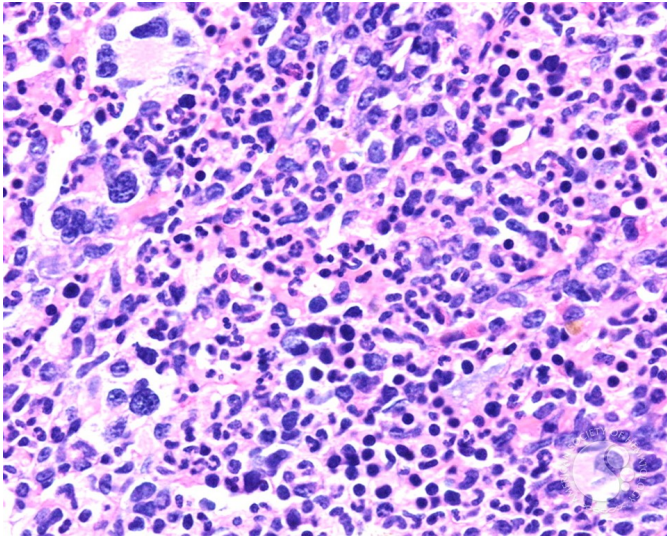
Image ID: 4031

Authors: John Lazarchick

Category: Myeloid Neoplasms and acute leukemia (WHO 2016) > Myeloproliferative Neoplasms (MPN) > MPN, unclassifiable

Description: The dysplastic megakaryocytes are seen more readily at higher magnification. The karyotype on cytogenetic analysis showed 46, XY, del(11)(q14q23) in all cells analyzed. Jak2 V617F mutation was also detected.





Copyright © 2026 American Society of Hematology. Copyright restrictions may apply.

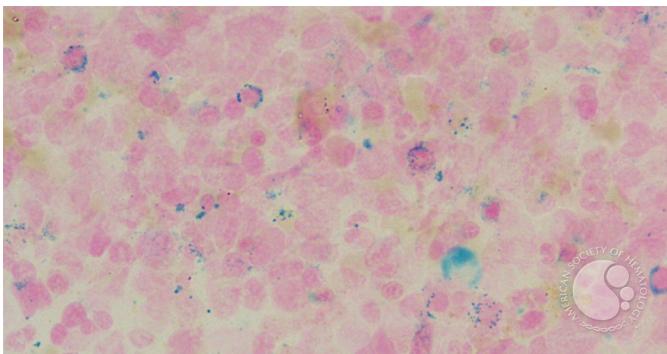
Refractory anemia with ringed sideroblast associated with thrombocytosis - 5.

Image ID: 4032

Authors: John Lazarchick

Category: Myeloid Neoplasms and acute leukemia (WHO 2016) > Myeloproliferative Neoplasms (MPN) > MPN, unclassifiable

Description: Multiple ringed sideroblasts are noted.



Copyright © 2026 American Society of Hematology. Copyright restrictions may apply.



ASH Image Bank™

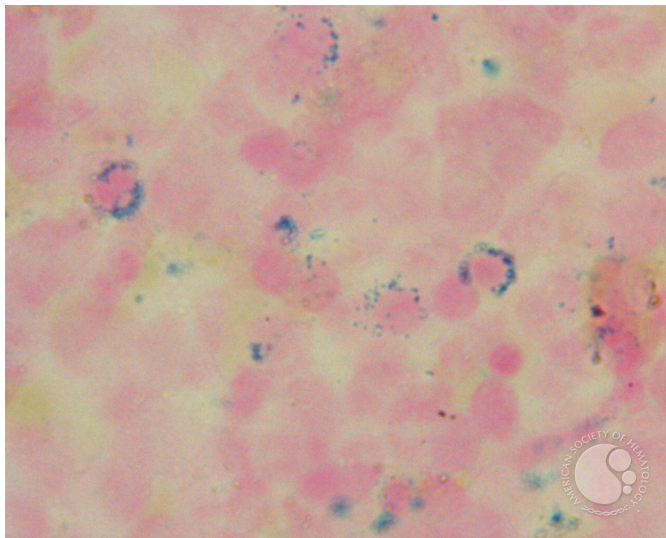
Refractory anemia with ringed sideroblast associated with thrombocytosis - 6.

Image ID: 4033

Authors: John Lazarchick

Category: Myeloid Neoplasms and acute leukemia (WHO 2016) > Myelodysplastic Syndromes (MDS) > MDS with Ring Sideroblasts (MDS-RS)

Description: The previous image is shown at higher magnification.



Copyright © 2026 American Society of Hematology. Copyright restrictions may apply.

