



ASH Image Bank™

Ehrlichiosis

Authors: John Lazarchick; Ginell Post;

Category: Infectious Disease

Number of Units: 4

Ehrlichiosis - 1.

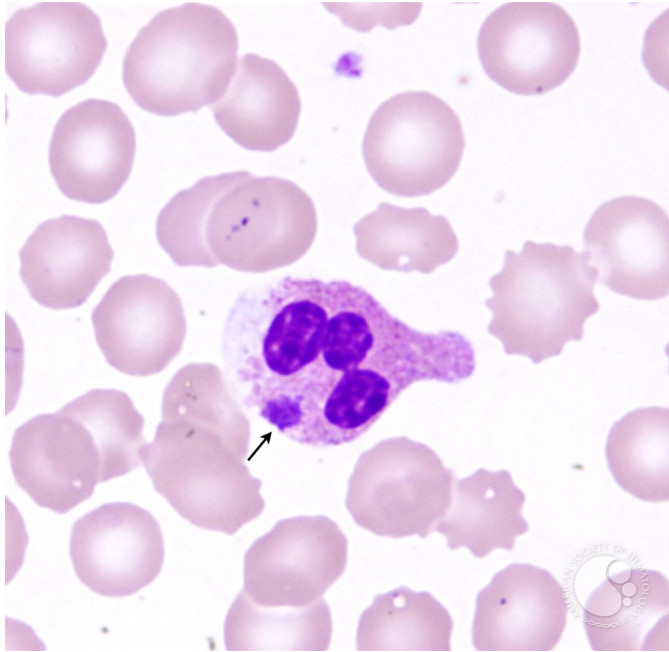
Image ID: 3614

Authors: John Lazarchick; Ginell Post;

Category: Infectious Disease > Bacteria

Description: Peripheral smear from a patient who presented with fever and generalized malaise is shown. Intracellular Ehrlichia organism (morula - arrow) is present. He was treated with a course of doxycycline and had an uneventful recovery.





Copyright © 2026 American Society of Hematology. Copyright restrictions may apply.

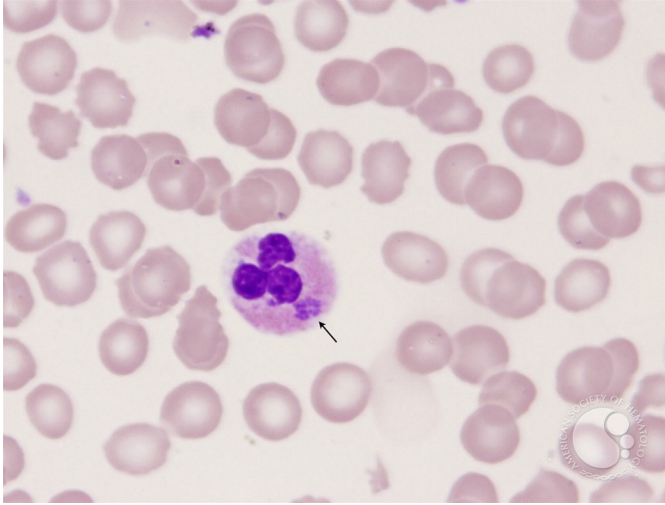
Ehrlichiosis - 2.

Image ID: 3615

Authors: John Lazarchick; Ginell Post;

Category: Infectious Disease > Bacteria

Description: The Ehrlichia morula (arrow) can be seen in the neutrophil as a gray amorphous cytoplasmic inclusion.



Copyright © 2026 American Society of Hematology. Copyright restrictions may apply.

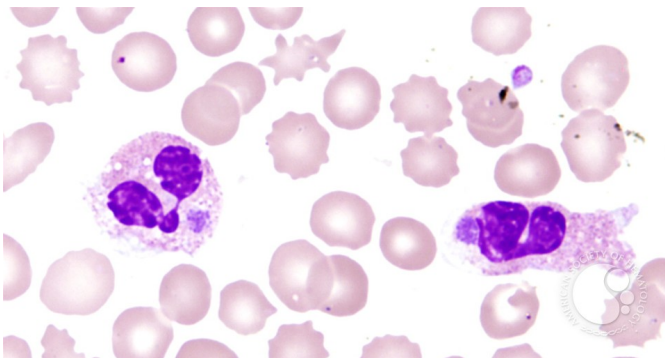
Ehrlichiosis - 3.

Image ID: 3616

Authors: John Lazarchick; Ginell Post;

Category: Infectious Disease > Bacteria > Ehrlichia

Description: Both neutrophils in this view have Ehrlichia inclusions.



Copyright © 2026 American Society of Hematology. Copyright restrictions may apply.



ASH Image Bank™

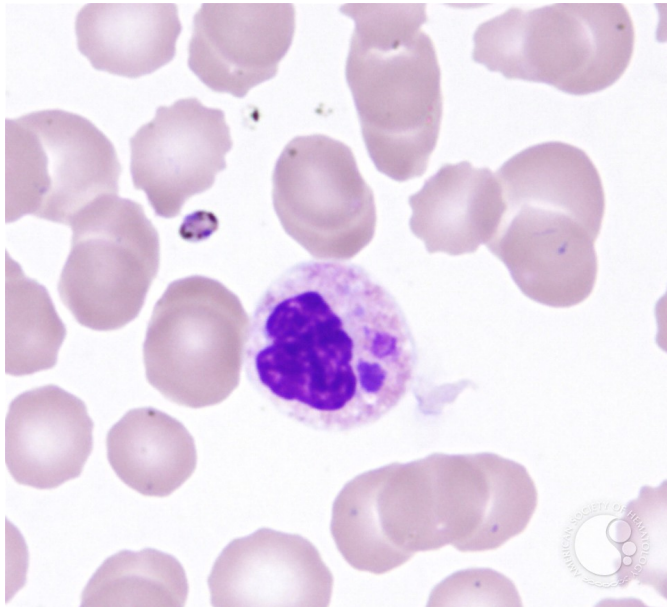
Ehrlichiosis - 4.

Image ID: 3617

Authors: John Lazarchick; Ginell Post;

Category: Infectious Disease > Bacteria

Description: In this view two Ehrlichia morula are present in the neutrophil. Another organism is also noted which is either extracellular or within a platelet.



Copyright © 2026 American Society of Hematology. Copyright restrictions may apply.

