



## Poikilocytosis

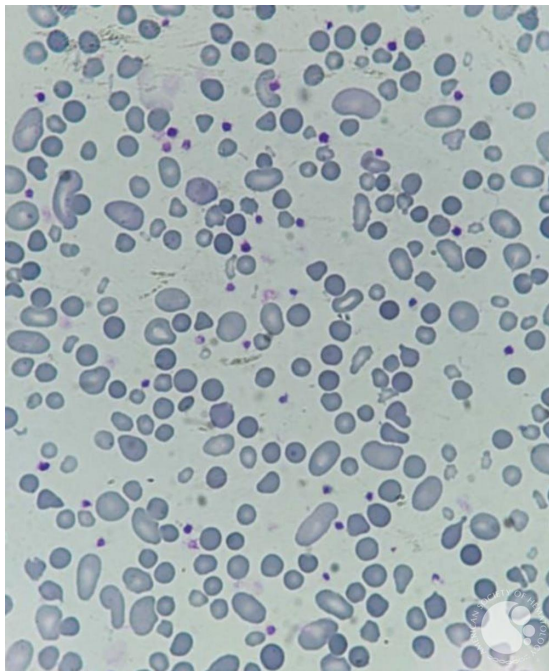
**Image ID:** 63821

**Authors:** Luiz Arthur Leite, PhD; João Vinícius Moraes Costa; Renato Matheus Souza de Jesus

**Category:** Red Cell: Other Disorders

### Description:

A 4-year-old girl presented in a peripheral blood smear poikilocytosis marked with the presence of Spherocytes, Ovalocytes, Schizocytes, Dacrocytes and a moderate Polychromasia. The hypothesis was a myelodysplastic syndrome with secondary immune hemolysis. (Leishman stain, original magnification x1000).&nbsp;



Copyright © 2026 American Society of Hematology. Copyright restrictions may apply.