



Plasmodium falciparum gametocytes 2

Image ID: 63450

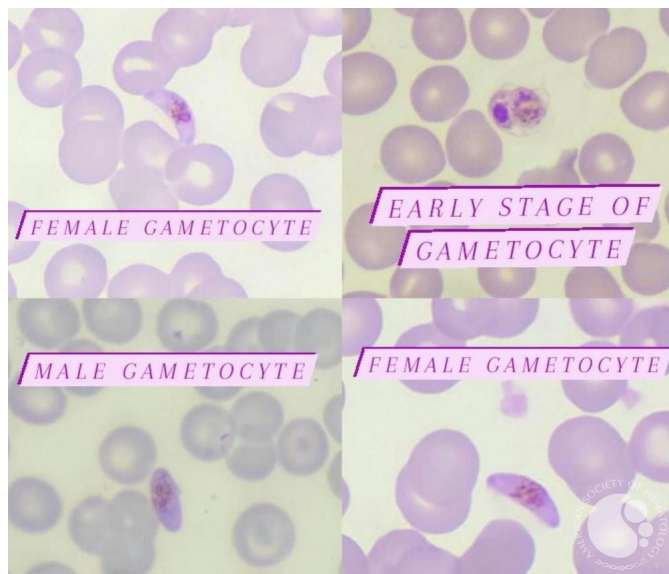
Authors: SOMIYA LAMRABAT, MD

Category: Infectious Disease > Parasites > Malaria > P. falciparum

Description:

Gametocytes of *P. falciparum* in a thin blood smear showing:

- An early stage gametocyte.
- Female gametocyte: Crescent/Banana-like shape with blue cytoplasm and a central mass of chromatin that consist of black rod-like granules.
- Male gametocytes: almost synonymous to the shape of females but fatter and less crescentic.



Copyright © 2026 American Society of Hematology. Copyright restrictions may apply.