



# ASH Image Bank™

## Granulocyte with malarial pigment

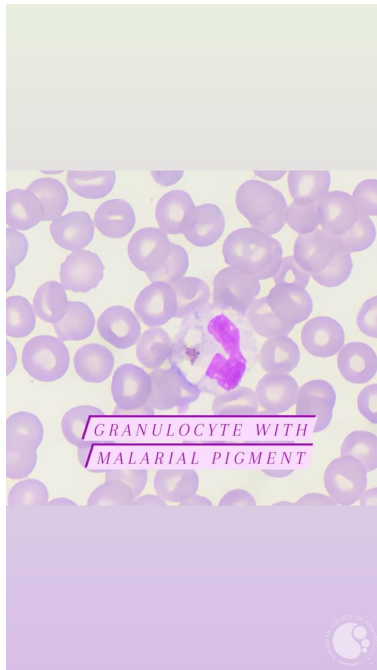
**Image ID:** 63448

**Authors:** Somiya LAMRABAT

**Category:** Infectious Disease > Parasites > Malaria > P. falciparum

### Description:

Thin blood smear : Reactional morphological abnormality of neutrophil granulocyte in malaria (hypossegmentation of the nucleus, and presence of malarial pigment in the cytoplasm).



Copyright © 2026 American Society of Hematology. Copyright restrictions may apply.

