



# ASH Image Bank™

## Megaloblastic anemia (100x). 2

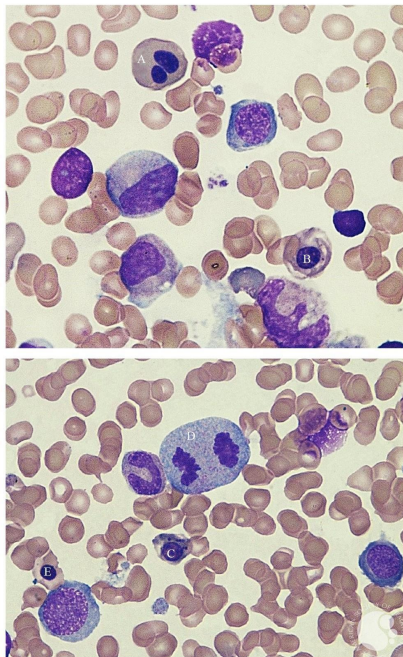
**Image ID:** 63317

**Authors:** Marianela Posada, MD; David Garrido, MD; Gimena Dos Santos, MD; Sofia Grille, MD, PhD

**Category:** Red Cell: Other Disorders > Megaloblastic Anemia

### Description:

Erythroid dysplasia (100x): Nuclear lobulation (A), defective haemoglobinisation with vacuolation (B), detached nuclear fragments (Howell-Jolly bodies) (C), mitotic figure (D), nucleocytoplasmic asynchrony (E).



Copyright © 2026 American Society of Hematology. Copyright restrictions may apply.

