



ASH Image Bank™

Megaloblastic anemia (100x). 1

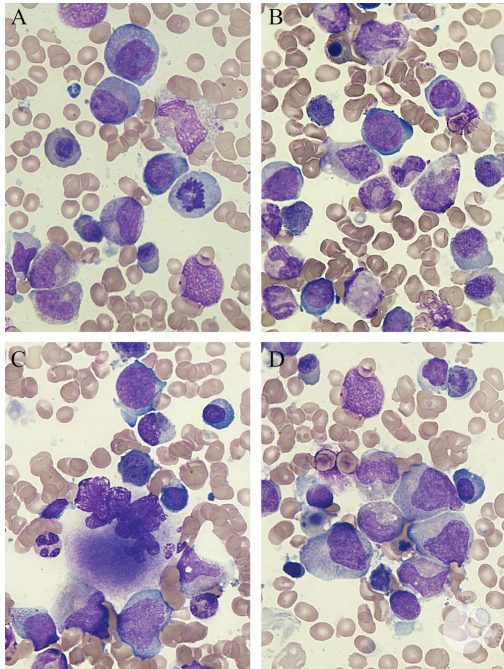
Image ID: 63316

Authors: Marianela Posada, MD; David Garrido, MD; Gimena Dos Santos, MD; Sofia Grille, MD, PhD

Category: Red Cell: Other Disorders

Description:

Megaloblastic anemia (100x).



Copyright © 2026 American Society of Hematology. Copyright restrictions may apply.

