



ASH Image Bank™

Refractory anemia with ring sideroblasts

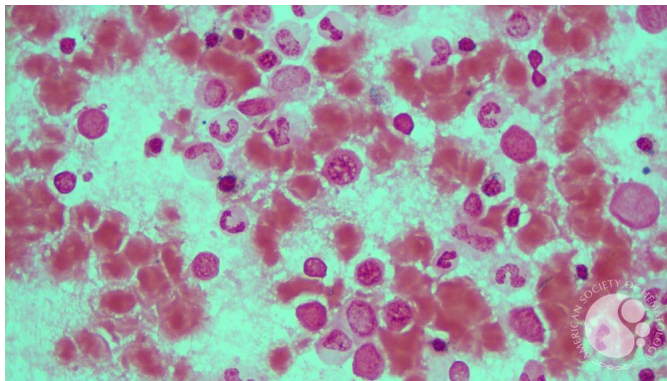
Image ID: 63016

Authors: Ke Xu

Category: Myeloid Neoplasms and acute leukemia (WHO 2016) > Myelodysplastic Syndromes (MDS) > MDS with Ring Sideroblasts (MDS-RS) > MDS-RS and single lineage dysplasia

Description:

A 73-year-old man presented with macrocytic anemia. Bone marrow aspirate iron stain showed 40% ring sideroblasts. Myeloid NGS identified pathogenic mutation in SF3B1 (VAF 39%).



Copyright © 2026 American Society of Hematology. Copyright restrictions may apply.

