



ASH Image Bank™

Blood-Tear Drop cells

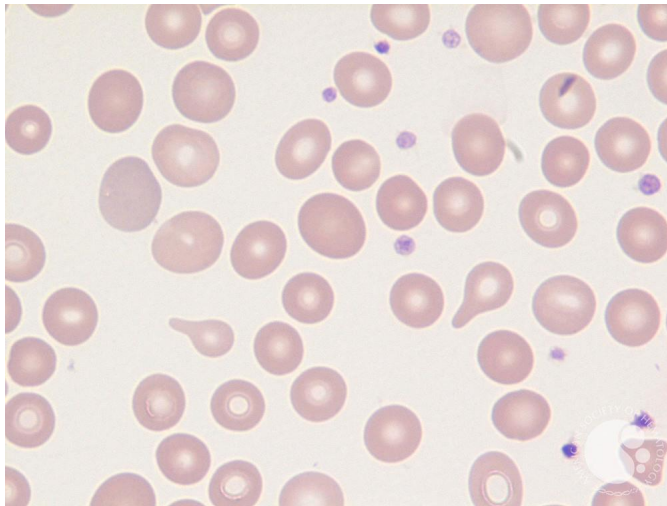
Image ID: 61857

Authors: Girish Venkataraman, MD, MBBS

Category: **Morphologic variants of normal cells** > Morphologic variants of Red Blood Cells/precursors > Normal Red blood cell morphology with resting lymphocyte for comparison > Poikilocytosis > Teardrop (dacrocyte) cells

Description:

Peripheral blood film showing two tear drop cells in the center of the field.



Copyright © 2026 American Society of Hematology. Copyright restrictions may apply.

