



ASH Image Bank™

MDS-RS

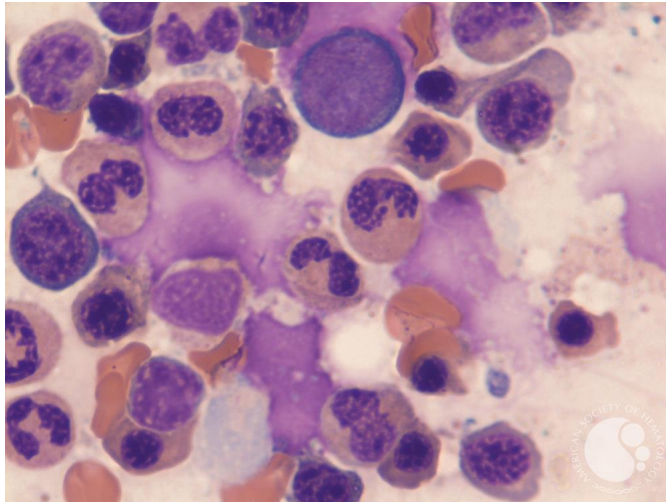
Image ID: 61623

Authors: Girish Venkataraman, MD, MBBS

Category: Myeloid Neoplasms and acute leukemia (WHO 2016) > Myelodysplastic Syndromes (MDS) > MDS with Ring Sideroblasts (MDS-RS) > MDS-RS and single lineage dysplasia

Description:

See reference case of MDS with ring sideroblasts for details of image and case.



Copyright © 2026 American Society of Hematology. Copyright restrictions may apply.

