



Hereditary pyropoikilocytosis

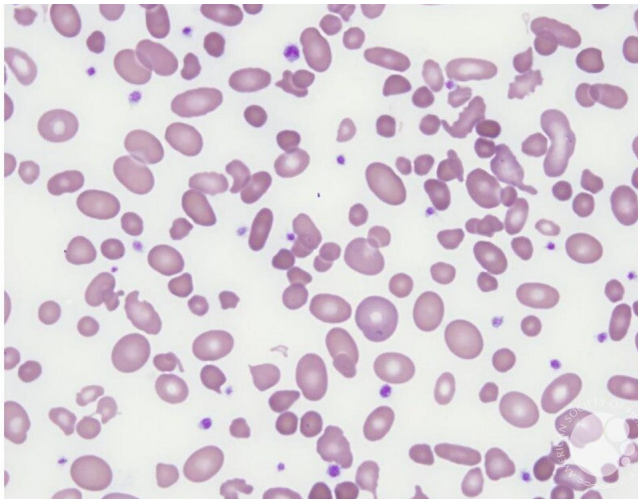
Image ID: 60300

Authors: Teresa Scordino

Category: **Morphologic variants of normal cells** > Morphologic variants of Red Blood Cells/precursors > Normal Red blood cell morphology with resting lymphocyte for comparison > Poikilocytosis

Description:

- The red blood cells in this patient with hereditary pyropoikilocytosis show marked variation in size (anisocytosis) and shape (poikilocytosis). The CBC would show an increased red cell distribution width (RDW).



Copyright © 2026 American Society of Hematology. Copyright restrictions may apply.