



ASH Image Bank™

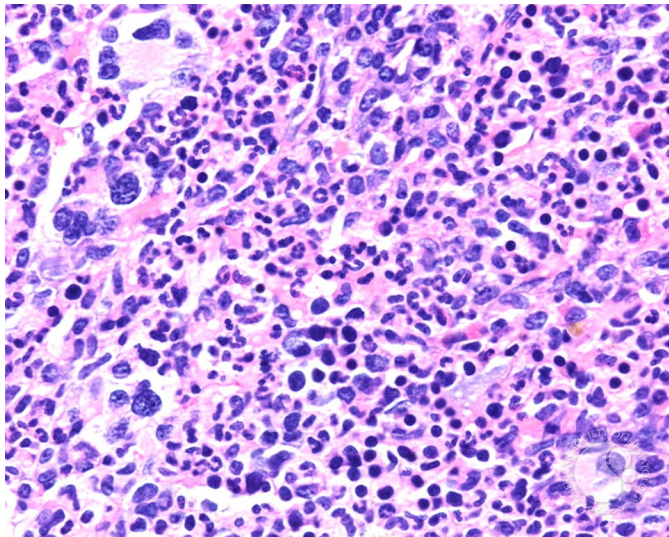
Refractory anemia with ringed sideroblast associated with thrombocytosis - 4.

Image ID: 4031

Authors: John Lazarchick

Category: Myeloid Neoplasms and acute leukemia (WHO 2016) > Myeloproliferative Neoplasms (MPN) > MPN, unclassifiable

Description: The dysplastic megakaryocytes are seen more readily at higher magnification. The karyotype on cytogenetic analysis showed 46, XY, del(11)(q14q23) in all cells analyzed. Jak2 V617F mutation was also detected.



Copyright © 2026 American Society of Hematology. Copyright restrictions may apply.

