



# ASH Image Bank™

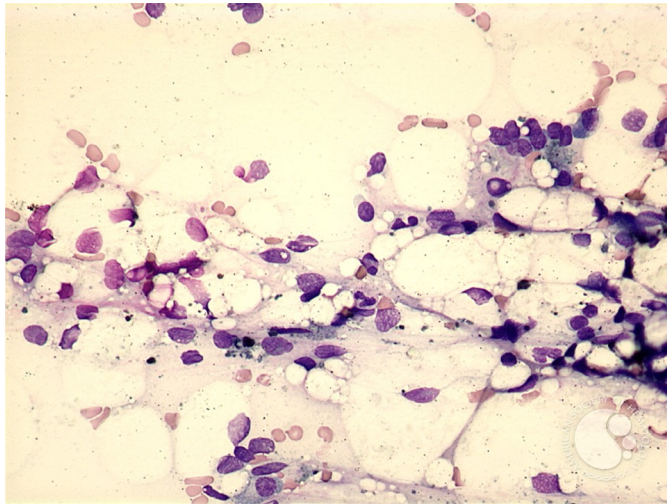
## Aplastic anemia - 3.

**Image ID:** 3911

**Authors:** Peter Maslak

**Category:** Bone marrow failure > Acquired Bone marrow failure > Acquired Aplastic Anemia

**Description:** A high-power view shows naked nuclei and debris laden histiocytes.



Copyright © 2026 American Society of Hematology. Copyright restrictions may apply.

