



# ASH Image Bank™

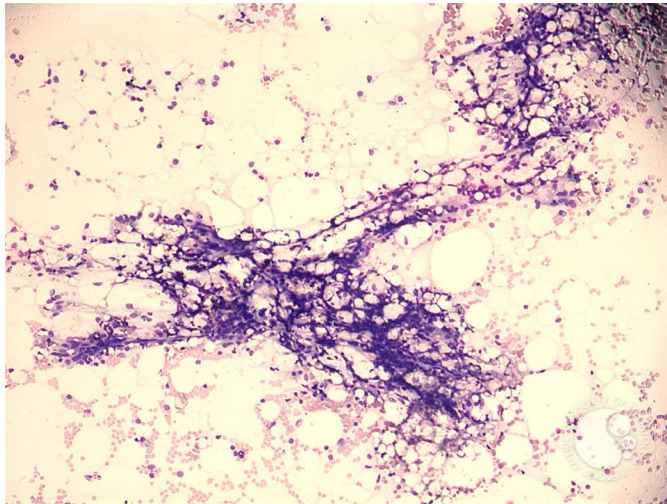
## Aplastic anemia - 1.

**Image ID:** 3909

**Authors:** Peter Maslak

**Category:** Bone marrow failure > Acquired Bone marrow failure > Acquired Aplastic Anemia

**Description:** Spicules are empty and generally devoid of hematopoietic elements.



Copyright © 2026 American Society of Hematology. Copyright restrictions may apply.