



ASH Image Bank™

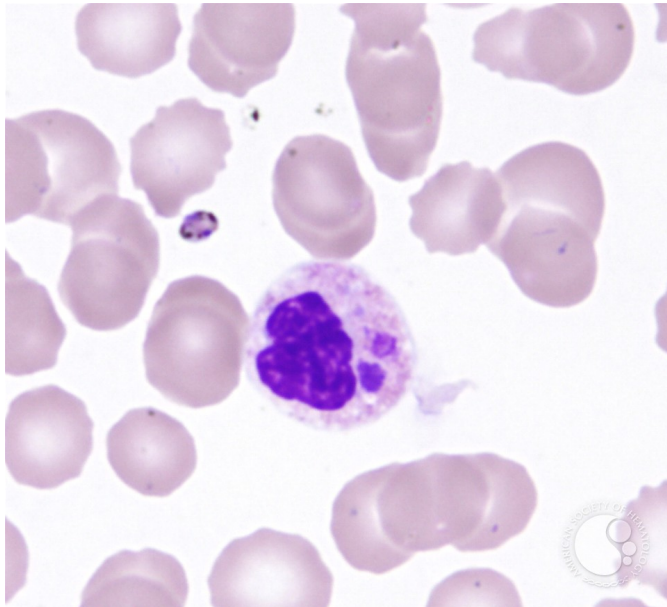
Ehrlichiosis - 4.

Image ID: 3617

Authors: John Lazarchick; Ginell Post;

Category: Infectious Disease > Bacteria

Description: In this view two Ehrlichia morula are present in the neutrophil. Another organism is also noted which is either extracellular or within a platelet.



Copyright © 2026 American Society of Hematology. Copyright restrictions may apply.

