



ASH Image Bank™

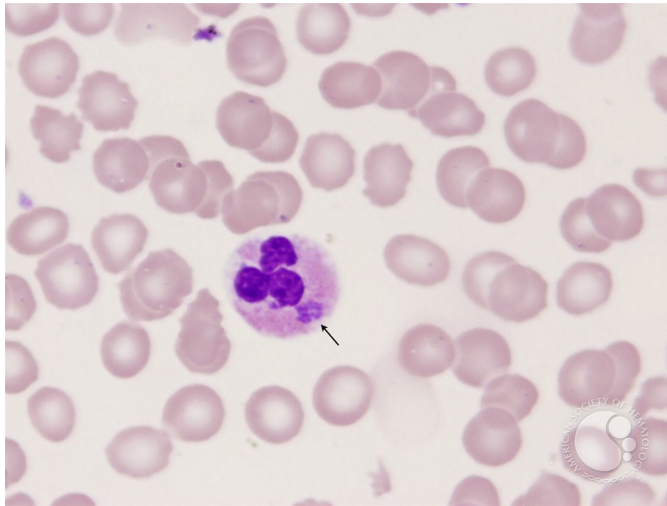
Ehrlichiosis - 2.

Image ID: 3615

Authors: John Lazarchick; Ginell Post;

Category: Infectious Disease > Bacteria

Description: The Ehrlichia morula (arrow) can be seen in the neutrophil as a gray amorphous cytoplasmic inclusion.



Copyright © 2026 American Society of Hematology. Copyright restrictions may apply.

