



ASH Image Bank™

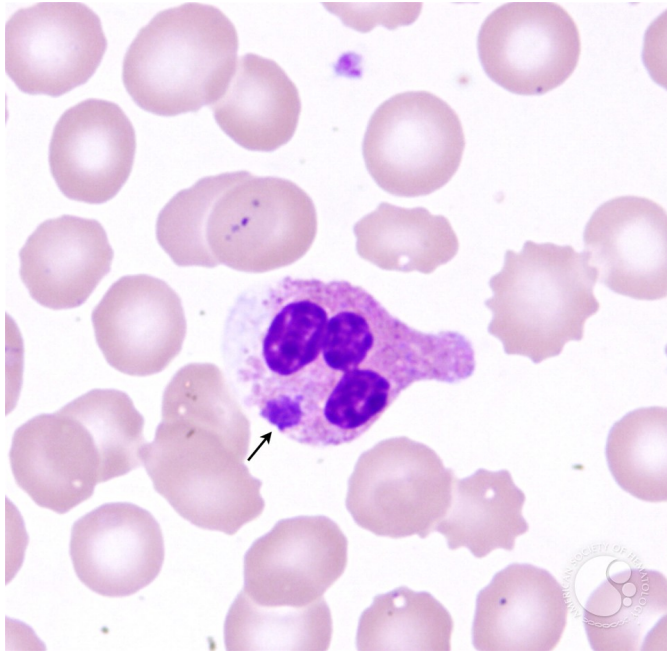
Ehrlichiosis - 1.

Image ID: 3614

Authors: John Lazarchick; Ginell Post;

Category: Infectious Disease > Bacteria

Description: Peripheral smear from a patient who presented with fever and generalized malaise is shown. Intracellular Ehrlichia organism (morula - arrow) is present. He was treated with a course of doxycycline and had an uneventful recovery.



Copyright © 2026 American Society of Hematology. Copyright restrictions may apply.

