



# ASH Image Bank™

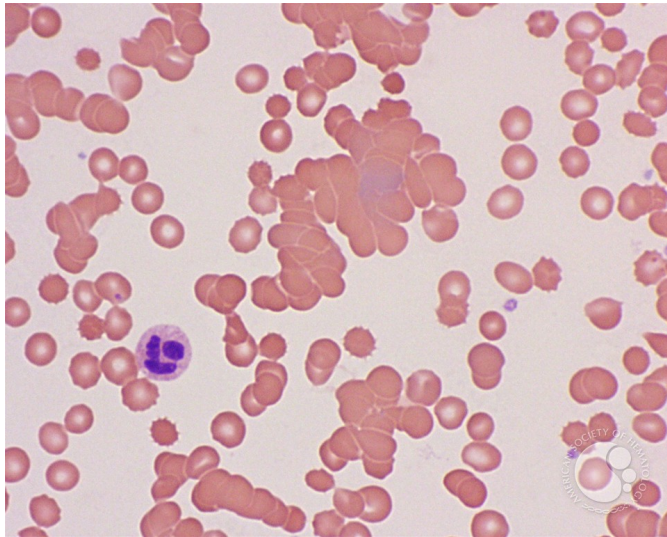
## RBC agglutination - 2.

**Image ID:** 3506

**Authors:** John Lazarchick; Ginell Post;

**Category: Red Cell:** Hemolytic Anemia (HA) > Autoimmune Hemolytic Anemias

**Description:** At higher magnification, variable-sized clumps of RBCs are noted with occasional spherocytes also evident.



Copyright © 2026 American Society of Hematology. Copyright restrictions may apply.

