



ASH Image Bank™

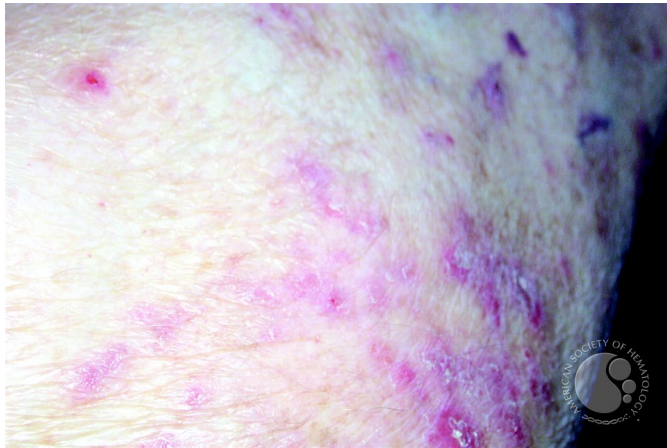
Leukemia Cutis - 2.

Image ID: 3421

Authors: Peter Maslak

Category: Myeloid Neoplasms and acute leukemia (WHO 2016) > Acute Myeloid Leukemia > Myeloid sarcoma

Description: Here the lesions appear as scaling papules.



Copyright © 2026 American Society of Hematology. Copyright restrictions may apply.