



ASH Image Bank™

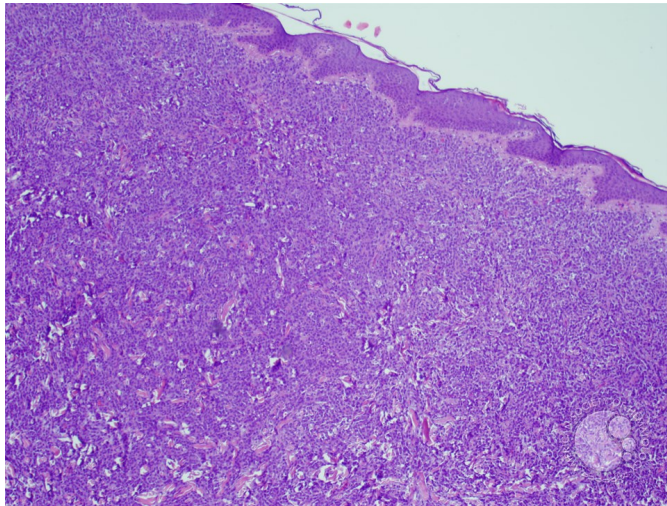
Myeloid Sarcoma -1

Image ID: 27898

Authors: Elizabeth Courville

Category: Myeloid Neoplasms and acute leukemia (WHO 2016) > Acute Myeloid Leukemia > Myeloid sarcoma

Description: 60 year old woman with a history of a chronic myeloid neoplasm, not further classifiable, presents with a skin nodule on her trunk



Copyright © 2026 American Society of Hematology. Copyright restrictions may apply.

