



ASH Image Bank™

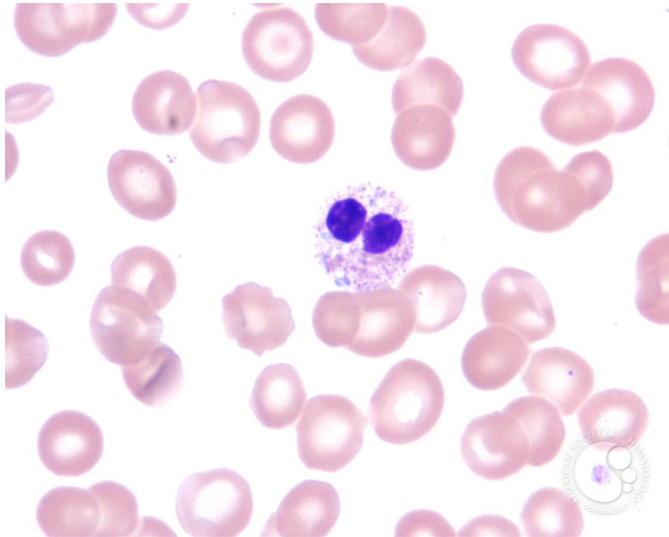
Pelger-Huet Anomaly - 5.

Image ID: 2698

Authors: John Lazarchick

Category: Laboratory Hematology > Basic cell morphology > Morphologic variants of white blood cells > Hyposegmented neutrophil

Description: The bi-lobed neutrophil in this image shows more clearly the toxic granulation, cytoplasmic vacuolization and bluish Dohle body.



Copyright © 2026 American Society of Hematology. Copyright restrictions may apply.

