



ASH Image Bank™

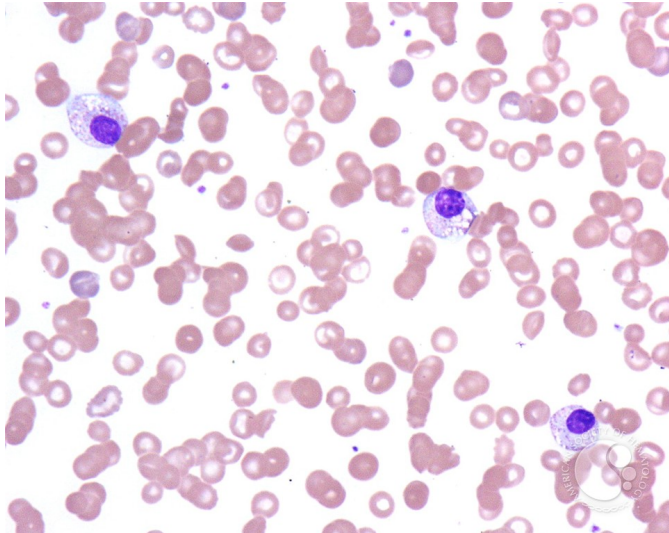
Pelger-Huet Anomaly - 3.

Image ID: 2696

Authors: John Lazarchick

Category: Laboratory Hematology > Basic cell morphology > Morphologic variants of white blood cells > Hyposegmented neutrophil

Description: The Pelger-Huet forms in this view show toxic granulation and cytoplasmic vacuolization. In addition, numerous target cells are present as well as polychromatophilic RBCs. The patient had been seen because of GI bleeding.



Copyright © 2026 American Society of Hematology. Copyright restrictions may apply.

