



# ASH Image Bank™

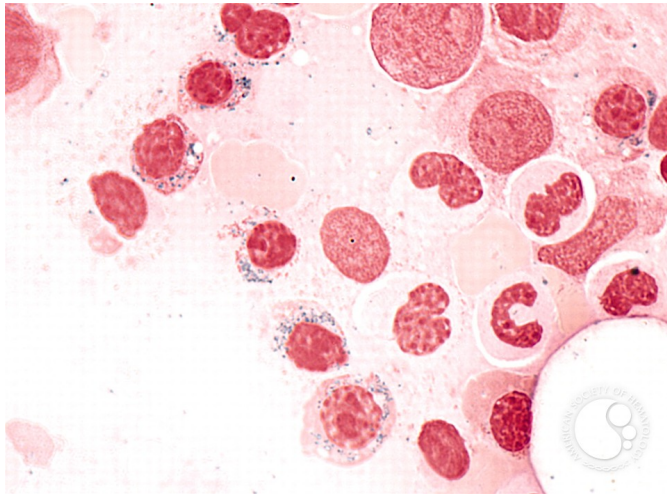
## Refractory Anemia with Ring Sideroblasts - 3.

**Image ID:** 2627

**Authors:** Peter Maslak

**Category:** Myeloid Neoplasms and acute leukemia (WHO 2016) > Myelodysplastic Syndromes (MDS) > MDS with Ring Sideroblasts (MDS-RS)

**Description:** Prussian blue stain is used to identify ring sideroblasts.



Copyright © 2026 American Society of Hematology. Copyright restrictions may apply.

