



ASH Image Bank™

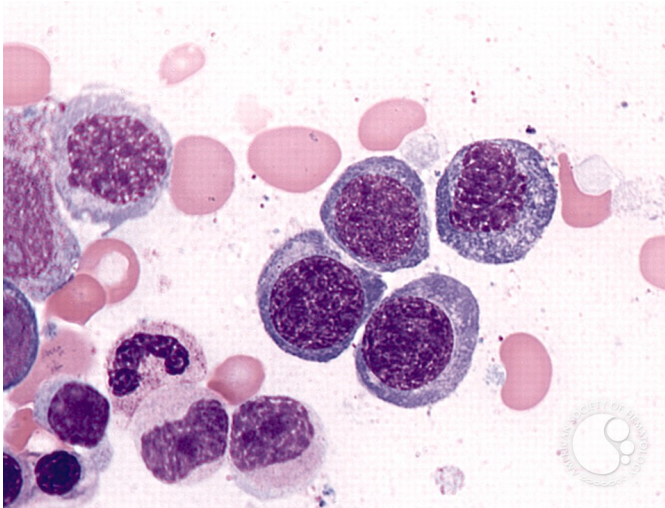
Refractory Anemia with Ring Sideroblasts - 1.

Image ID: 2625

Authors: Peter Maslak

Category: Myeloid Neoplasms and acute leukemia (WHO 2016) > Myelodysplastic Syndromes (MDS) > MDS with Ring Sideroblasts (MDS-RS)

Description: Bone marrow aspirate is hypercellular with erythroid hyperplasia and prominent dyserythropoiesis.



Copyright © 2026 American Society of Hematology. Copyright restrictions may apply.

