



ASH Image Bank™

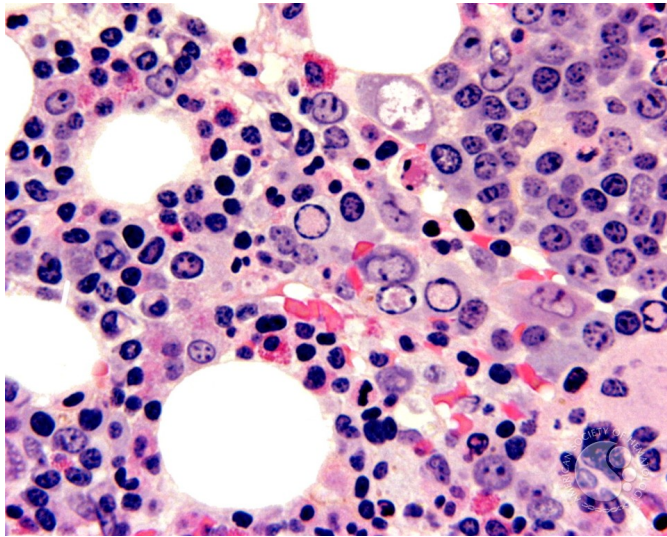
Parvovirus Inclusions - 4.

Image ID: 2610

Authors: John Lazarchick

Category: Underproduction Anemias > Pure Red Cell Aplasia

Description: The parvovirus nuclear inclusions (clear areas) in the erythroblasts are more evident on the biopsy of the marrow.



Copyright © 2026 American Society of Hematology. Copyright restrictions may apply.