



# ASH Image Bank™

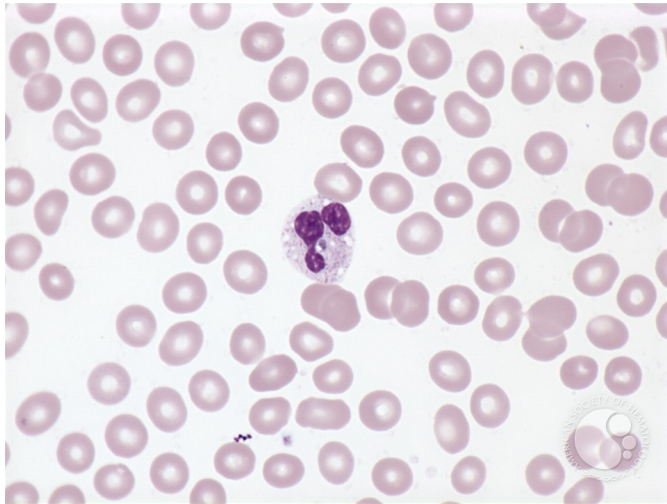
## Ehrlichiosis - 2.

**Image ID:** 1817

**Authors:** Peter Maslak; Lisa Southern;

**Category:** Infectious Disease > Bacteria > Ehrlichia

**Description:** Morula (arrow) in a granulocyte of a patient with ehrlichiosis. Vacuoles are also noted in the cytoplasm.



Copyright © 2026 American Society of Hematology. Copyright restrictions may apply.

