



# ASH Image Bank™

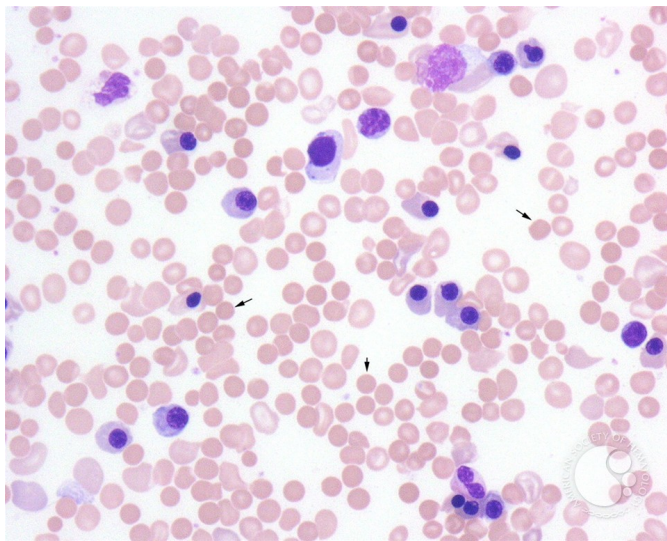
## Erythroblastosis Fetalis - 2.

**Image ID:** 1784

**Authors:** John Lazarchick

**Category: Red Cell:** Hemolytic Anemia (HA) > Autoimmune Hemolytic Anemias

**Description:** Spherocytes are present (arrows).



Copyright © 2026 American Society of Hematology. Copyright restrictions may apply.

