



ASH Image Bank™

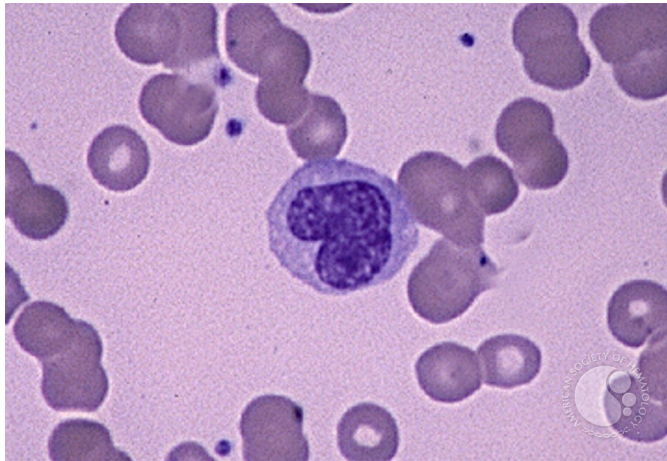
Monocyte - 1.

Image ID: 1591

Authors: Peter Maslak

Category: Laboratory Hematology > Basic cell morphology > Morphologic variants of white blood cells

Description: A monocyte in the peripheral blood has pale blue cytoplasm with a convoluted nucleus (MacNeal Tetrachrome 1000X)



Copyright © 2026 American Society of Hematology. Copyright restrictions may apply.