



ASH Image Bank™

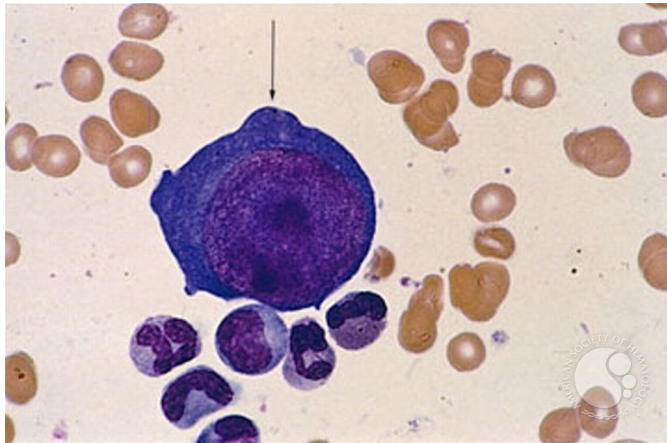
Pure Red Cell Aplasia (PRCA) – parvovirus infection - 3.

Image ID: 1550

Authors: Stanley Schrier

Category: Underproduction Anemias > Pure Red Cell Aplasia

Description: The marrow aspirate shows very much diminished erythropoiesis, and the giant proerythroblast characteristic of parvovirus infection.



Copyright © 2026 American Society of Hematology. Copyright restrictions may apply.

