



ASH Image Bank™

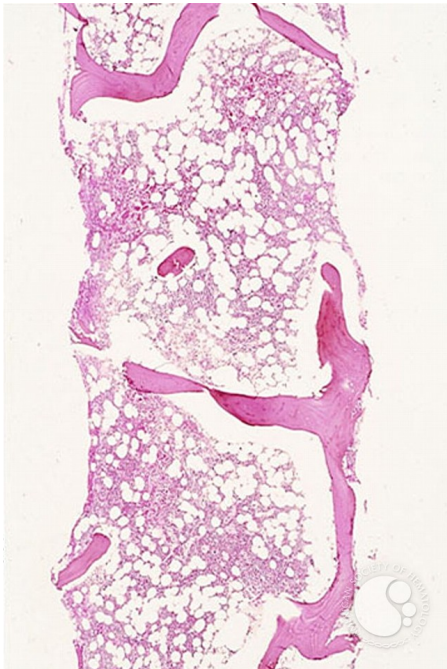
Pure Red Cell Aplasia (PRCA) – parvovirus infection - 2.

Image ID: 1549

Authors: Stanley Schrier

Category: Underproduction Anemias > Pure Red Cell Aplasia

Description: Bone marrow biopsy is normal. There are no infiltrates, and the cellularity is within normal limits.



Copyright © 2026 American Society of Hematology. Copyright restrictions may apply.

