



ASH Image Bank™

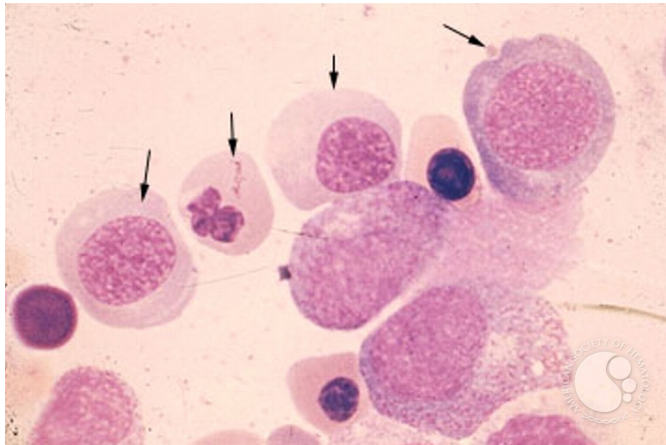
Pernicious Anemia - 3.

Image ID: 1547

Authors: Stanley Schrier

Category: Red Cell: Other Disorders > Megaloblastic Anemia

Description: Bone Marrow Aspirate showing megaloblastic erythropoiesis with very fine nuclear chromatin and asynchrony of development of nucleus (immature) and cytoplasm (more mature).



Copyright © 2026 American Society of Hematology. Copyright restrictions may apply.