



ASH Image Bank™

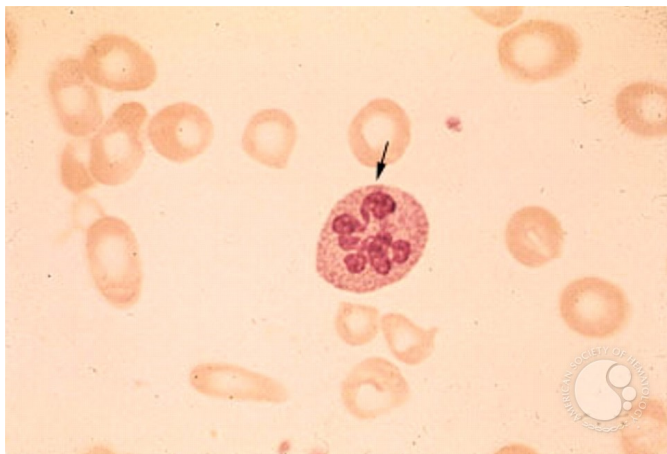
Pernicious Anemia - 2.

Image ID: 1546

Authors: Stanley Schrier

Category: Red Cell: Other Disorders > Megaloblastic Anemia

Description: Note the hypersegmented neutrophil (7-8 lobes).



Copyright © 2026 American Society of Hematology. Copyright restrictions may apply.