



# ASH Image Bank™

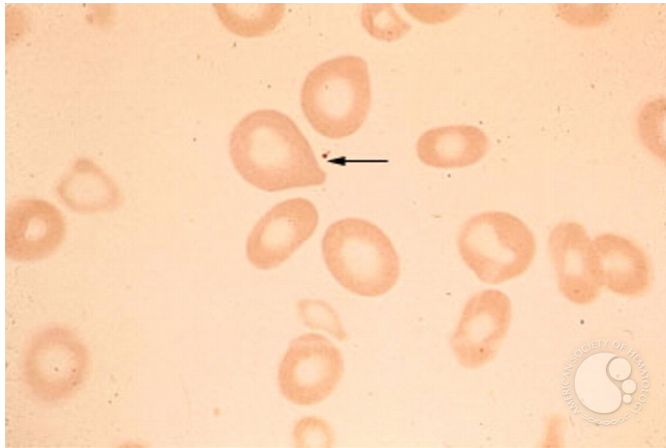
## Pernicious Anemia - 1B

**Image ID:** 1545

**Authors:** Stanley Schrier

**Category: Red Cell:** Other Disorders > Megaloblastic Anemia

**Description:** Note the macro-ovalocytes characteristic of vitamin B12 or folate deficiency states.



Copyright © 2026 American Society of Hematology. Copyright restrictions may apply.

