



ASH Image Bank™

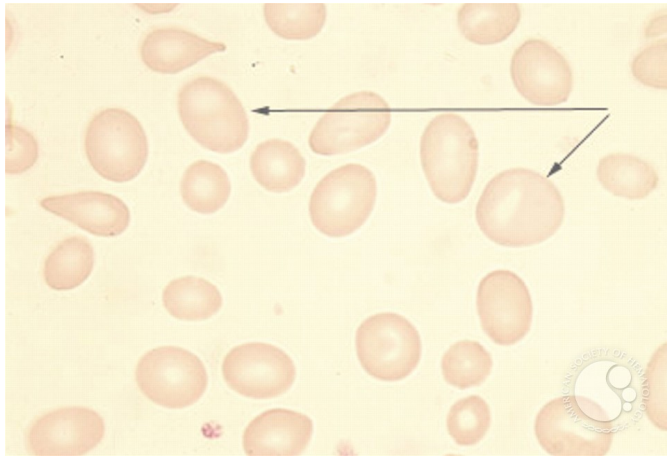
Pernicious Anemia - 1A

Image ID: 1544

Authors: Stanley Schrier

Category: Red Cell: Other Disorders > Megaloblastic Anemia

Description: Note the macro-ovalocytes characteristic of vitamin B12 or folate deficiency states.



Copyright © 2026 American Society of Hematology. Copyright restrictions may apply.