



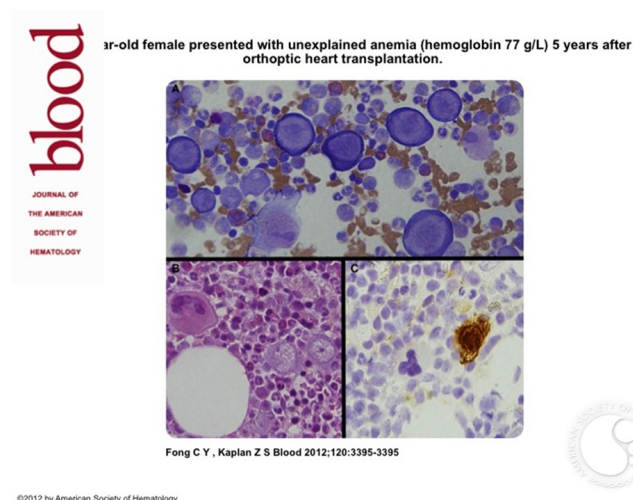
## Parvovirus B19–induced pure red cell aplasia in a heart transplant recipient

Image ID: 14466

Authors: Chun Yew Fong and Zane S. Kaplan

Category: Underproduction Anemias > Pure Red Cell Aplasia

**Description:** The patient presented with unexplained anemia (hemoglobin 77 g/L) 5 years after orthoptic heart transplantation. She was being treated with high-dose immunosuppression. The blood film demonstrated a normochromic normocytic anemia. The white cell and platelet counts were normal. There was reticulocytopenia ( $1 \times 10^9/L$ , 0.04%) and an elevated erythropoietin (356 U/mL; normal, 5-18.5 U/mL) with normal B12, folate, and iron studies. No evidence of thymoma or lymphoma was found as judged by radiologic testing and flow cytometry. A bone marrow examination showed atypical giant pronormoblasts with markedly reduced maturing granulopoiesis (panels A and B) that was characteristic of parvovirus-induced pure red cell aplasia. Adjacent megakaryocytes demonstrate the relative size of the atypical giant pronormoblasts in panel B. Immunohistochemistry for parvovirus B19 was positive on the marrow biopsy (panel C). Parvovirus B19 DNA was detected by PCR; however, serology (IgM/IgG) was negative.



Copyright © 2026 American Society of Hematology. Copyright restrictions may apply.