



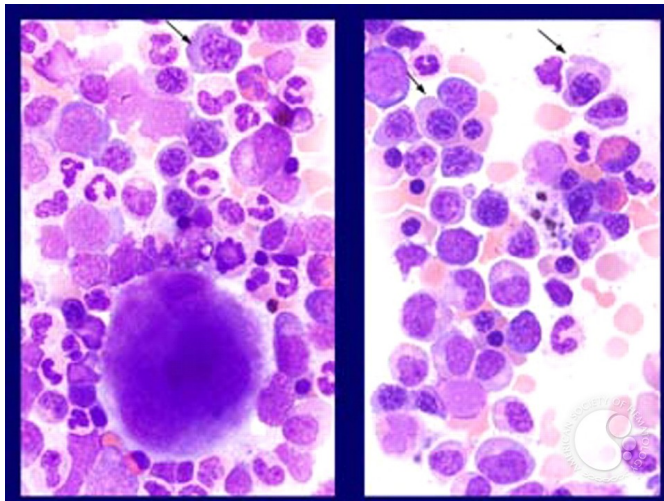
## Myelodysplastic Syndrome: Refractory Anemia with Ringed Sideroblasts (RARS) - 4.

Image ID: 1439

**Authors:** James W Vardiman

**Category:** Myeloid Neoplasms and acute leukemia (WHO 2016) > Myelodysplastic Syndromes (MDS) > MDS with Ring Sideroblasts (MDS-RS)

**Description:** Refractory anemia with ringed sideroblasts (RARS). Bone marrow aspirate smear (Wright-Giemsa stain). The two panels in this slide illustrate that the megakaryocytes and the granulocytes show normal morphology. The erythroid precursors in this slide do show some mild nuclear/cytoplasmic dyssynchrony (arrow).



Copyright © 2026 American Society of Hematology. Copyright restrictions may apply.