



ASH Image Bank™

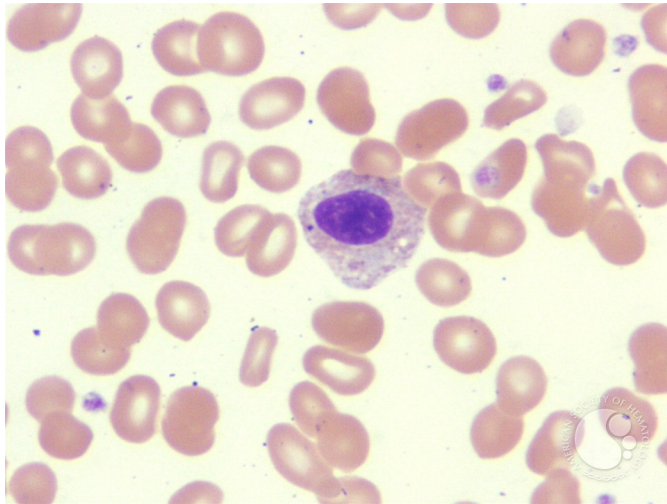
Pelger-Huet anomaly variants - 3.

Image ID: 1263

Authors: John Lazarchick

Category: Laboratory Hematology > Basic cell morphology > Morphologic variants of white blood cells > Hyposegmented neutrophil > True Pelger Huet

Description: The image illustrates another example of Pelger-Huet anomaly.



Copyright © 2026 American Society of Hematology. Copyright restrictions may apply.