



ASH Image Bank™

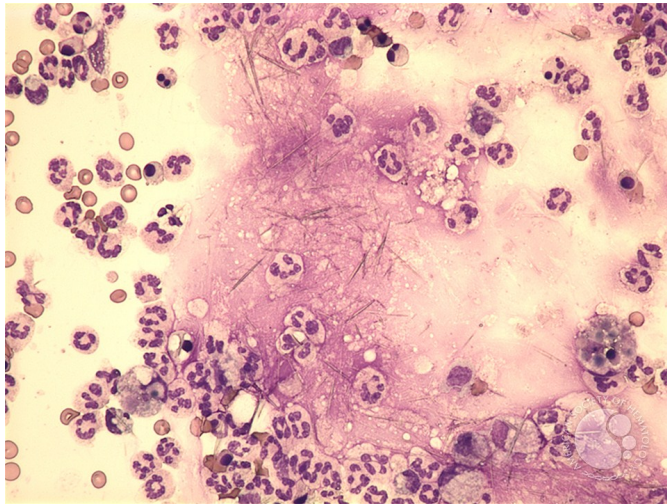
Gout - synovial fluid

Image ID: 13493

Authors: Peter Maslak, Lisa Southern

Category: Laboratory Hematology > Special hematology tests

Description: Granulocytes are increased in the fluid aspirated from the patient's wrist. Crystals are also noted



Copyright © 2026 American Society of Hematology. Copyright restrictions may apply.

